



**PATIENT**

Phoebe Rumsey

**SPECIES**

Canine

**BREED**

Cavalier

**SEX**

Female Spayed

**AGE**

12 years

**WEIGHT**

21.7lbs

**INTERPRETED BY**

Maggie Machen  
Lamy, DVM  
DACVIM (Cardiology)

**IMAGING PERFORMED BY**

Pamela Harrigan,  
RDMS

**HOSPITAL NAME**

Wood River Animal  
Hospital

**REFERRING VET**

Dr. Fischer

**INVOICE**

24195

**DATE**

5/15/22

**PRESENTING CLINICAL SIGNS**

History: Recheck echo. History chronic valvular disease - Stage B2. Currently doing well at home with no clinical signs.

-Pertinent previous echo findings (10/29/21 Keith Blass, DVM, DACVIM-Cardiology): LA 2.94 cm; LA:Ao 1.54; LV 3.10 cm; mild LAE; mild-moderate MR: mild TR (2.11 m/s). Current medications: Pimobendan 2.5mg BID.

**ECHOCARDIOGRAM FINDINGS**

2D, m-mode, color flow and Doppler imaging is available.

**Left ventricle:** The LV diameter is increased with hyperdynamic myocardial function. LV wall thicknesses are normal.

**Left atrium:** The left atrium is moderately dilated.

**Mitral valve:** The mitral valve is diffusely thickened with mild prolapse into the left atrial lumen. Moderate eccentric mitral regurgitation with a normal velocity.

**Aortic valve/aorta:** The aortic valve is normal in morphology and mobility. Normal aortic outflow velocity; laminar flow. Trace aortic insufficiency.

**Right ventricle:** Normal right ventricular diameter and morphology indicating no overt evidence of pulmonary arterial hypertension.

**Right atrium:** Normal RA dimension.

**Tricuspid valve:** The tricuspid valve appears mildly thickened with mild tricuspid regurgitation. Normal velocity.

**Pulmonic valve/pulmonary artery:** The pulmonic valve is normal in morphology and mobility. No pulmonic insufficiency. Normal RVOT velocity; laminar flow.

**Pericardium/other:** No pericardial or pleural effusion noted. No obvious cardiac masses.

**Heart rhythm:** ECG reveals a sinus rhythm with an average HR of 110bpm.

**2-Dimensional Measurements**

Ao diam (cm)	1.76
LA diam (cm)	3.0
LA:Ao (Swe)	1.6
IVS thickness (cm)	0.74
LVID diastole (cm)	3.4
PW thickness (cm)	0.73
LVID systole (cm)	1.76
FS (%)	48

**Doppler Measurements**

PV Vmax (m/s)	0.5
AoV Vmax (m/s)	1.3
MR Vmax (m/s)	5.5
TR Vmax (m/s)	2.3
TR PG (mmHg)	21

**INTERPRETATION OF THE FINDINGS**

Chronic degenerative valve disease persists with evidence of stability. Moderate mitral regurgitation is unchanged with stable left heart dimensions. A small tricuspid leak is noted; however, no obvious pulmonary hypertension is documented. A small aortic leak is noted, and a baseline blood pressure is recommended. No additional issues are identified.

Given these findings, continue Pimobendan as prescribed. No obvious indication for additional medications. Continued assessment of progression in the future will help predict long term outcome, however prognosis is guarded at this stage (B2).

**RECOMMENDATIONS**

- Continue heart muscle support Pimobendan 0.3mg/kg PO q12h.
- Baseline BP with monitoring every 6 months.



**PATIENT**

Phoebe Rumsey

**SPECIES**

Canine

**BREED**

Cavalier

**SEX**

Female Spayed

**AGE**

12 years

**WEIGHT**

21.7lbs

**INTERPRETED BY**

Maggie Machen  
 Lamy, DVM  
 DACVIM (Cardiology)

**IMAGING PERFORMED BY**

Pamela Harrigan,  
 RDCS

**HOSPITAL NAME**

Wood River Animal  
 Hospital

**REFERRING VET**

Dr. Fischer

**INVOICE**

24195

**DATE**

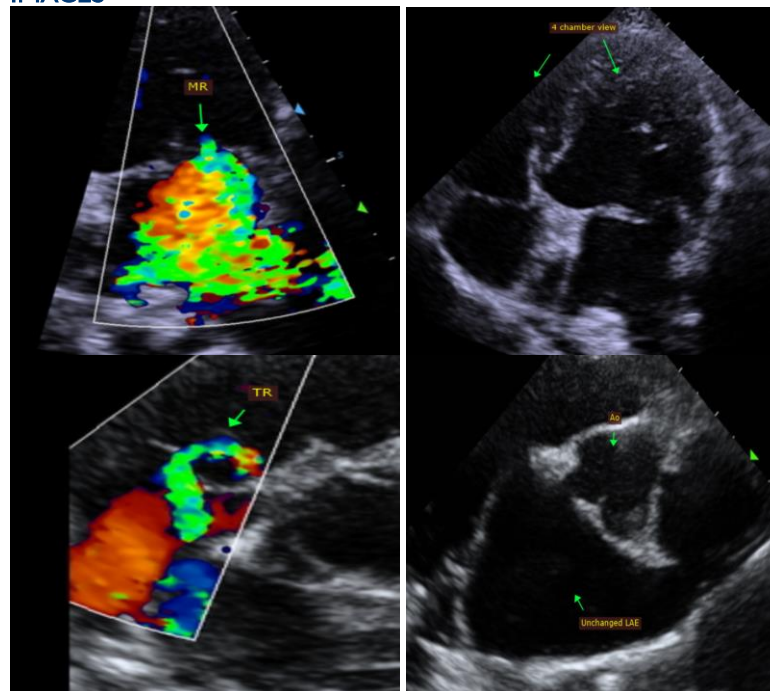
5/15/22

- Omega fatty acid supplementation and mild salt restriction may be of some long-term benefit.
- Anesthetic risk is considered mild if needed. Cardiac protective drug choices (opioid/benzodiazepine premedication, propofol or alfaxalone induction, isoflurane gas) are recommended. Pre-oxygenate for 5-10 minutes prior to induction. Monitor for arrhythmias, hypotension, and hypoxia both intra and post-operatively and intervene as necessary. Mild IV fluid restriction is recommended to avoid fluid overload. Avoid heart rate stimulating drugs such as atropine unless clinically indicated.
- Monitor for development of a cough, labored breathing, exercise intolerance or collapse episodes.

**PLAN**

- Recommend conservative monitoring with a recheck echocardiogram in 6 months, sooner if any development of clinical signs.

**IMAGES**



The information and recommendations provided are based on the images presented by the referring veterinarian. No evaluation can be communicated regarding pathology that was not visible in the image/video clips provided.

Thank you for this referral. This report was generated using transcription software, and minor dictation errors may be present. If the clinical or image interpretation does not parallel your findings or if I can be of any further assistance, please contact me.

Maggie Machen Lamy, DVM  
 Diplomate of the American College of Veterinary Internal Medicine (Cardiology)  
 info@sonopath.com